

Comparison of Radiological Assessments Patellar Resurfacing with Retention for Grade IV Osteoarthritis in Patellofemoral Joint accomplished Total Knee Arthroplasty

K.E. Eshnazarov, MD;
Jong-Keun Seon, MD, PhD, Associate Professor;
Eun-Kyoo Song, MD, PhD, Professor

Chonnam National University Hwasun Hospital,
322 Seoyang-ro Hwasun-eup. Hwasun-gun Jeonnam, Korea, 58128

Рентгенологическая оценка послеоперационных изменений у пациентов с остеоартрозом пателлофemorального сустава IV степени, перенесших тотальную артропластику коленного сустава с эндопротезированием суставной поверхности надколенника или без него

K.E. Eshnazarov, MD;
Jong-Keun Seon, MD, PhD, Associate Professor;
Eun-Kyoo Song, MD, PhD, Professor

Chonnam National University Hwasun Hospital,
322 Seoyang-ro Hwasun-eup. Hwasun-gun Jeonnam, Korea, 58128

Introduction. The purpose of this prospective study was to compare radiological outcomes after total knee arthroplasty (TKA) with or without patellar resurfacing in patients with grade IV osteoarthritis on patellofemoral joint.

Material and methods. 123 cases with Kellgren–Lawrence grade IV osteoarthritis on patellofemoral joint were enrolled for this study. At the operating room, they were randomly assigned to undergo patella resurfacing (62 cases) or patella retention (61 cases). Among them, 114 cases that could be followed for more than 2 years were included in this study (resurfacing group; 59 cases, retention group; 55 cases). Preoperative and postoperative radiological outcomes (mechanical femorotibial angle, patellar tilt and congruence angles) were evaluated and compared between two groups.

Results. Preoperative radiological measures shows not significant difference between patellar tilt ($P = 0.13$), mechanical femorotibial angles ($P = 0.62$) and congruence angle ($P = 0.37$). Despite the difference performed methods of surgery, postoperative radiological assessment outcomes between two groups were almost identical Patellar tilt ($P = 0.47$), mechanical femorotibial angles ($P = 0.34$) and congruence angle ($P > 0.05$).

Conclusion. Obtained almost the same satisfactory radiological outcomes after patella resurfacing and retention groups after total knee replacement allows us to conclude that, primary TKA without patella resurfacing is a good treatment option in patients with high grade osteoarthritis of the patellofemoral joint.

Index terms: knee osteoarthritis; total knee arthroplasty; patella resurfacing; radiological assessment.

For citation: Eshnazarov K.E., Jong-Keun Seon, Eun-Kyoo Song. Comparison of Radiological Assessments Patellar Resurfacing with Retention for Grade IV Osteoarthritis in Patellofemoral Joint accomplished Total Knee Arthroplasty. *Vestnik Rentgenologii i Radiologii (Journal of Roentgenology and Radiology, Russian journal)*. 2016; 97 (1): 28–32 (in Russ.). DOI: 10.20862/0042-4676-2016-97-1-28-32

For correspondence: Kamolhuja E. Eshnazarov; E-mail: kamolhuja77@mail.ru

Цель данного проспективного исследования – сравнение результатов, получаемых с помощью рентгенологического исследования у пациентов после тотальной артропластики коленного сустава (ТАКС) с эндопротезированием суставной поверхности надколенника или без него при остеоартрозе пателлофemorального сочленения IV ст.

Материал и методы. В исследование были включены 123 пациента с остеоартрозом пателлофemorального сустава IV ст. (по классификации Kellgren–Lawrence). В операционной пациенты были рандомизированы на две группы: оперативное вмешательство с эндопротезированием надколенника (62 случая) и с сохранением его суставной поверхности (61 случай). Из них 114 пациентов находились под наблюдением более 2 лет (с эндопротезированием надколенника – 59, с сохранением суставной поверхности надколенника – 55 человек). В двух группах оценивались и сравнивались до- и послеоперационные изменения, выявляемые при рентгенографии (механический феморотибиальный угол, угол наклона надколенника, угол конгруэнтности надколенника).

Результаты. При дооперационном рентгенологическом исследовании пациентов не было выявлено достоверных различий между группами по величине угла наклона надколенника ($p = 0,13$), феморотибиального угла ($p = 0,62$) и угла конгруэнтности надколенника ($p = 0,37$). Несмотря на различный хирургический подход, послеоперационная оценка данных параметров также не показала достоверных различий между группами ($p = 0,47$, $p = 0,34$ и $p > 0,05$ соответственно).

Заключение. Удовлетворительные результаты рентгенологического исследования как после операции тотальной артропластики коленного сустава с заменой суставной поверхности надколенника, так и без нее свидетельствуют о том, что первичная ТАКС без эндопротезирования надколенника является эффективным способом хирургического лечения пациентов с тяжелой степенью остеоартрита пателлофemorального сочленения.

Ключевые слова: остеоартрит коленного сустава; тотальная артропластика коленного сустава; эндопротезирование суставной поверхности надколенника; рентгенологическая оценка.

Information about authors:

Eshnazarov Kamolhuja, <http://orcid.org/0000-0002-2494-2436>

Jong-Keun Seon, <http://orcid.org/0000-0002-6920-5659>

Eun-Kyoo Song, <http://orcid.org/0000-0003-0765-8545>

Conflict of interest. The authors declare no conflict of interest.

Funding. The study had no sponsorship.

Received 18 October 2015
Accepted 14 December 2015

Для цитирования: Eshnazarov K.E., Jong-Keun Seon, Eun-Kyoo Song. Comparison of Radiological Assessments Patellar Resurfacing with Retention for Grade IV Osteoarthritis in Patellofemoral Joint accomplished Total Knee Arthroplasty. *Vestnik Rentgenologii i Radiologii (Journal of Roentgenology and Radiology, Russian journal)*. 2016; 97 (1): 28–32 (in Russ.). DOI: 10.20862/0042-4676-2016-97-1-28-32

Для корреспонденции: Kamolhuja E. Eshnazarov; E-mail: kamolhuja77@mail.ru

Introduction

For several years, in the patients with knee osteoarthritis widely use total knee arthroplasty (TKA), because the destruction and degree of deterioration of the articular surface cartilage are more occurring [1, 2].

The equipment technologies, surgery techniques, results of treatment knee osteoarthritis improved during the last decade and reached the excellent clinical success of total knee replacement (TKR) but controversy remains concerning whether or not to resurface the patella [3–5].

By many authors have been conducted number of randomized controlled trials and clinical studies [4, 6]. Randomized controlled trials constitute the most reliable source of evidence for the evaluation of the efficacy of a potential intervention. But most of these studies include all degree of osteoarthritis of the patellofemoral joint [6]. And on the other hand numerous research were conducted to certain solves of the questions resurfacing or retention patellofemoral joint [7, 8, 10]. Despite radiological measures has higher informative value for TKR [11], not many authors were published materials studying patellar resurfacing problems in high degree osteoarthritis performing TKR.

The purpose of this prospective study was to compare radiological outcomes after TKA with or without patellar resurfacing in patients with grade IV osteoarthritis on patellofemoral joint. We enrolled only patients with Kellgren–Lawrence grade IV or International Cartilage Repair Society (ICRS) grade IV osteoarthritis on patellofemoral joint performed primary TKA.

Material and methods

To study our goal we have gathered all the materials of the patient with osteoarthritis grade IV on patellofemoral joint (Figure 1), undergoing TKA in Chonnam National University Hospital during the 2004–2013 years (123 cases). The patients assessed radiological outcomes were divided into two groups, 62 cases of patellar resurfacing and 61 cases of patella retention group. Among them, 114 cases that could be followed for more than 2 years were included in this study, 59 cases of resurfacing group and 55 cases of retention group.

In patellar resurfacing group were 59 knees of 42 patients which average age equal 66.3 year and in retention group 55 knees of 49 patients with average age were 65.6 year. For the comparison of preoperative radiological state of the patient we evaluated and compared outcomes regarding the mechanical femorotibial angles ($^{\circ}$, valgus), patellar tilt ($^{\circ}$) and congruence angle ($^{\circ}$) in both of group of patient (Figure 2). Intraoperatively individually was measured patellar

thickness for determination implant size. In patients almost were used patellar implants with 8.0–9.0 mm thickness.

All our patient were performed cemented primary TKA with a medial parapatellar approach, total 54 knees were operated using computer navigation E-motion technics. TKA accomplished with patellar resurfacing in the first group and patellar retention in second groups. When patellar retention was performed, osteophytes of the patella were removed and marginal electrocauterization was carried out. In 23 patients were performed TKA in both knees and 68 cases were only in one side. When surgery made in one of knees 38 cases were in right and 30 were in left side.

Postoperatively during the follow two years were taken roentgenography the operating knees and re-defined radiological outcomes (the mechanical femorotibial angles, patellar tilt and congruence angle) in both of group of patient (Figure 3).

Our authors objectively and widely researched each question

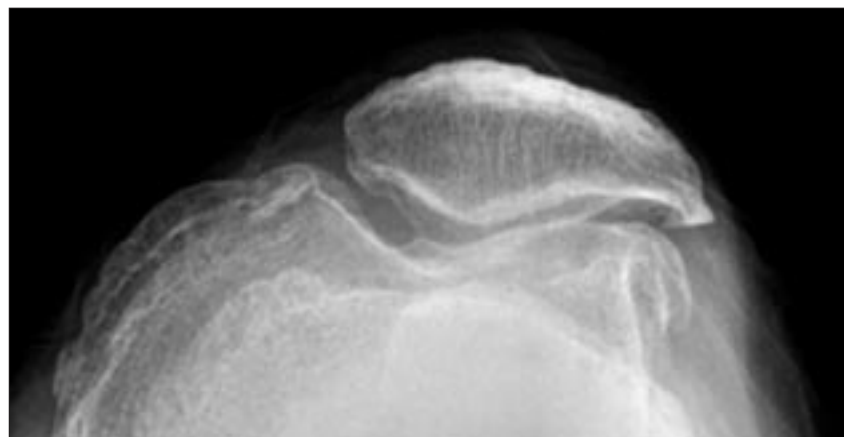


Figure 1. Preoperative patellofemoral osteoarthritis Grade IV

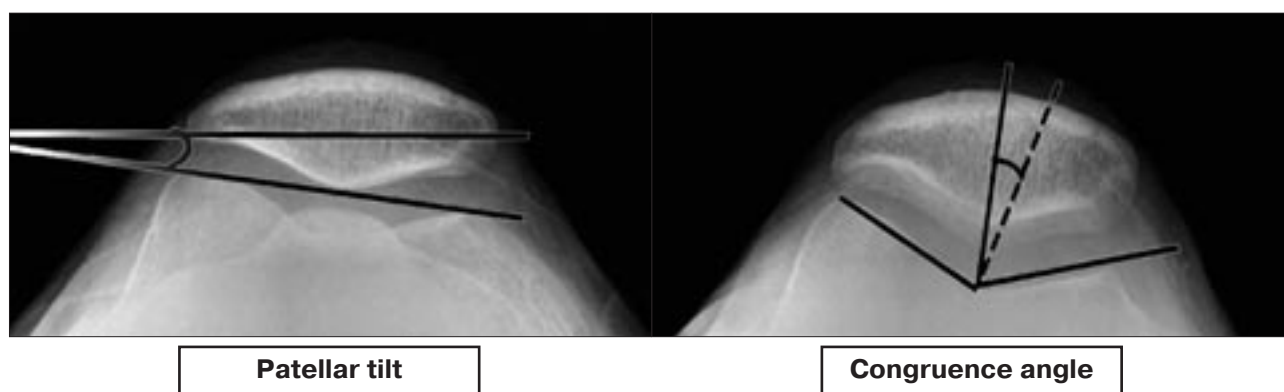


Figure 2. Radiological assessment methods before surgery

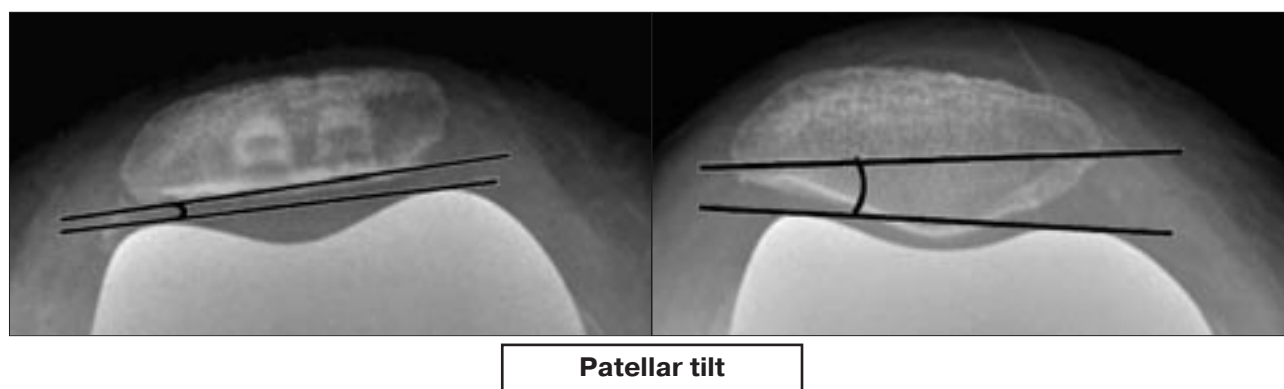


Figure 3. Patellar tilt assessments after surgery in resurfacing and retention patellofemoral joint

installed on separately parts, each issues were discussed in comprehensive approaches. For a visual processing and demonstrate our research work we used Microsoft Word and Microsoft Excel 2010.

Results

Radiological finds of our study have two important features, variation preoperative indications to postoperative outcomes and opportunity to assess difference between resurfacing and retention group patellofemoral joint.

Measures before surgery shows not significant difference patellar tilt of 5° ($P = 0.13$), mechanical femorotibial angles ($P = 0.62$) and congruence angle ($P = 0.37$) between patellar resurfacing and not resurfacing groups (Table). Despite the difference performed methods of surgery, postoperative radiological assessment outcomes indicated to receiving good results within two groups and almost were identi-

cal for both of groups patient (Patellar tilt ($P = 0.47$), mechanical femorotibial angles ($P = 0.34$) and congruence angle ($P > 0.05$)). However the preoperative femorotibial mechanical angle of patents in resurfacing group ranged from 3.64° to 18.02° and from 1.98° to 19.36° in retention group, postoperative results shows good result in both groups, and the mechanical angle average mean after surgery for both group was 0.69 degree.

Second finding of our study results was definition not significant difference postoperative radiological outcomes assessment

between patellar resurfacing and retention groups. Preoperative measures of patellar tilt indicated that development of osteophytes and deformation of the patellar surface led to change this radiological mark, average patellar tilt angle for both group was 11.4 ± 6.6 degree. However postoperatively were obtained satisfied results in both group of patients (1.75 ± 1.12 in resurfacing group and 2.68 ± 1.34 in retention group, P -value = 0.47). During the assessment preoperative congruence angle in both groups were identified large ranges of sulcus angle difference between

Preoperative radiological assessment

Assessment methods	Resurfacing G	Retention G	P-value
Mechanical femorotibial angle ($^\circ$, varus)	10.83 ± 7.19	10.67 ± 8.69	0.62
Patellar tilt ($^\circ$)	10.68 ± 6.21	12.12 ± 6.98	0.13
Congruence angle ($^\circ$)	18.9 ± 11.41	22.4 ± 10.84	0.37

patients ($141.3^\circ \pm 3.8^\circ$). Despite deepened patellar groove in prosthesis which we used the postoperative congruence angle assessment results in resurfacing group and in retention group was almost equal. Postoperative radiological assessment mechanical femorotibial angle ($^\circ$, varus) difference within researched groups was not significant (P -value = 0.34), in resurfacing group -0.81 ± 3.27 and 0.12 ± 3.58 in retention group.

Discussion

Despite the excellent clinical success of total knee arthroplasty (TKA), controversy remains concerning whether or not to resurface the patella [2, 14]. J. Farr et al. finds shows that patient with not resurfaced knees had slightly better satisfaction than patellar resurfaced patients [9] and with correctly execution TKA, resurfacing patella is unnecessary [10, 13]. But after obtaining good clinical outcomes and because of the possibility of a subsequent deterioration of the patella with osteoarthritis in long-term follow-up, other group of researches consider that resurfacing of the patella during primary total knee arthroplasty is one of the best solution [12, 16]. When osteoarthritis have not severe pain even there is many changes in the cartilage, treatment knee arthritis manage without patellofemoral arthroplasty. In TKA performed without resurfacing, the patella contact force does not significantly increase and cartilage contact stress doesn't increase and this lead to prevent most expected complications. Nevertheless the risk of postoperative complications is highest in patellar resurfacing group than not resurfacing group [3]. To choose a solution resurfacing or retention patellar surface we must pay attention to a lot of criteria but preoperative radiological diagnostic measures and checking postoperative radiological results of the treatment are indispensable and important for all TKA.

Assessment of the patellar cartilage intraoperative and make deci-

sion on patellar resurfacing are trustworthy in patient undergoing TKR after osteoarthritis, however, despite the patellar cartilage was damaged, only the status of the patellar articular cannot be determining main factor for patellar resurfacing [4]. Most of patients with pathology of the knee osteoarthritis radiologically determined patellofemoral osteoarthritis with severe of grade [16, 17]. However we include in our study only the high degree of patellofemoral osteoarthritis. Determination of the grade of osteoarthritis using with Kellgren–Lawrence grade widely used by many researchers [18, 19]. Based on these decisions we enrolled only patients with Kellgren–Lawrence grade IV or ICRS grade IV osteoarthritis on patellofemoral joint performed primary TKA.

Definition and study patellofemoral congruence angle in patient widely used for diagnosis and measure clinical outcomes of the surgery [15]. Because this method has some limits the researchers needs another techniques for achieve their purpose [20]. Scrutiny patellar tilt and mechanical femorotibial angles are one of the informative methods for study indications and outcomes of TKA [11, 21]. To get more detailed radiological results, we used once preoperative and postoperative determination difference between patellar tilt, mechanical femorotibial angles and congruence angle.

In our small study we explore difference between only some roentgenologic methods with osteoarthritis grade IV in patients performing primary TKA. We could not add to our study of MRI, CT and other radiological methods of investigation. However these methods also frequently used in practice today and our study limitation caused leave these aspects remain open.

Conclusion

Obtained almost the same satisfactory radiological outcomes after patella resurfacing and retention

groups after TKR allows us to conclude that, primary TKA without patellar resurfacing is a good treatment option in patients with high grade osteoarthritis of the patellofemoral joint.

Conflict of interest

The authors declare no conflict of interest.

Funding

The study had no sponsorship.

References

1. Pastides P.S., Shenoy R., Nathwani D. The patella in total knee replacement. *Orthopedics and Traumatology Journal*. 2013; 27 (6): 372–8.
2. Schindler O.S. The controversy of patellar resurfacing in total knee arthroplasty: Ibisne in medio tutissimus? *Knee Surgery, Sports Traumatology, Arthroscopy Journal*. 2012; 20 (7): 1227–44.
3. Roberts D.W., Hayes T.D., Tate Ch.T., Lesko J.P. Selective Patellar Resurfacing in Total Knee Arthroplasty: A Prospective, Randomized, Double-Blind Study. *Journal of Arthroplasty*. 2015; 30 (2): 216–22.
4. Ilkyu Han, Chong Bum Chang, Yeon Gwi Kang, Su Won Yoon, Sang Cheol Seong, Tae Kyun Kim. Intraobserver and Interobserver Reliability of the Assessment of the Patellar Articular Cartilage in Osteoarthritic Patients Undergoing Total Knee Arthroplasty. *Journal of Arthroplasty*. 2006; 21 (4): 567–71.
5. Karam J.A., Higuera C.A., Smith E.B., Sharkey P.F. Patellofemoral Arthritis. *Journal of Operative Techniques in Orthopaedics*. 2012; 22 (4): 196–202.
6. Mayman D., Bourne R.B., Rorabeck C.H., Vaz M., Kramer J. Resurfacing Versus Not Resurfacing the Patella in Total Knee Arthroplasty. *Journal of Arthroplasty*. 2003; 18 (5): 541–5.
7. Glynn A., Huang R., Mortazavi J., Parvizi J. The Impact of Patellar Resurfacing in Two-Stage Revision of the Infected Total Knee Arthroplasty. *Journal of Arthroplasty*. 2014; 29 (7): 1439–42.

8. Garcia R.M., Kraay M.J., Goldberg V.M. Isolated Resurfacing of the Previously Unresurfaced Patella Total Knee Arthroplasty. *Journal of Arthroplasty*. 2010; 25 (5): 754–8.
9. Farr J., Lattermann Ch. Management of Patellofemoral Arthritis Without Arthroplasty. *Seminars in Arthroplasty Journal*. 2009; 20 (3): 136–41.
10. Thompson N.W., Ruiz A.L., Breslin E., Beverland D.E. Total Knee Arthroplasty Without Patellar Resurfacing in Isolated Patellofemoral Osteoarthritis. *Journal of Arthroplasty*. 2001; 16 (5): 607–12.
11. Cherian J.J., Kapadia B.H., Banerjee S., Jauregui J.J., Issa K., Mont M.A. Mechanical, Anatomical, and Kinematic Axis in TKA: Concepts and Practical Applications. *Journal of Current Reviews in Musculoskeletal Medicine*. 2014; 7 (2): 89–95.
12. Zhong-tang Liu, Pei-liang Fu, Hai-shan Wu, Yunli Zhu. Patellar reshaping versus resurfacing in total knee arthroplasty – Results of a randomized prospective trial at a minimum of 7 years' follow-up. *Knee Journal*. 2012; 19 (3): 198–202.
13. Singerman R., Gabriel S.M., Maheshwer C.B., Kennedy J.W. Patellar Contact Forces With and Without Patellar Resurfacing in Total Knee Arthroplasty. *Journal of Arthroplasty*. 1999; 14 (5): 603–9.
14. Helmy N., Anglin C., Greidanus N.V., Masri B.A. To Resurface or Not to Resurface the Patella in Total Knee Arthroplasty. *Clinical Orthopaedics and Related Research Journal*. 2008; 466 (11): 2775–83.
15. Urch S.E., Tritle B.A., Shelbourne K.D., Gray T. Axial Linear Patellar Displacement A New Measurement of Patellofemoral Congruence. *American Journal of Sports Medicine*. 2009; 379 (5): 970–3.
16. Farrokhi Sh., O'Connell M., Fitzgerald G.K. Altered gait biomechanics and increased knee-specific impairments in patients with coexisting tibiofemoral and patellofemoral osteoarthritis. *Gait & Posture*. 2015; 41 (1): 81–5.
17. Hinman R.S., Lentzos J., Vicenzino B., Crossley K.M. Is Patellofemoral Osteoarthritis Common in Middle-Aged People With Chronic Patellofemoral Pain? *Arthritis Care and Research Journal*. 2014; 66: 1252–7.
18. Katsuragi J., Sasho T., Yamaguchi S., Sato Y., Watanabe A., Akagi R., Muramatsu Y., Mukoyama S., Akatsu Y., Fukawa T., Endo J., Hoshi H., Yamamoto Y., Sasaki T., Takahashi K. Hidden osteophyte formation on plain X-ray is the predictive factor for development of knee osteoarthritis after 48 months – data from the Osteoarthritis. *Osteoarthritis and Cartilage Journal*. 2015; 23 (3): 383–90.
19. Schiphof D., Oei E.H.G., Hofman A., Waarsing J.H., Weinans H., Bierma-Zeinstra S.M.A. Sensitivity and associations with pain and body weight of an MRI definition of knee osteoarthritis compared with radiographic Kellgren and Lawrence criteria: a population-based study in middle-aged female. *Osteoarthritis and Cartilage Journal*. 2014; 22 (3): 440–6.
20. Merchant A.C. Radiography of the patellofemoral joint. *Operative Techniques in Sports Medicine Journal*. 1999; 7: 59–64.
21. Gomes L.S., Bechtold J.E., Gustilo R.B. Patellar prosthesis positioning in total knee arthroplasty: a roentgenographic study. *Clinical Orthopaedics Related Research Journal*. 1988; 236: 72–81.

Received 18 October 2015

Accepted 14 December 2015